

Comparison of the Efficacy of Topical Triamcinolone in Orabase and Curcumin in Orabase in Oral Graft-versus-Host Disease

Arash Mansourian ¹, Babak Bahar ², Mahdieh Sadat Moosavi ³, Massoud Amanlou ⁴, Shahabodin Babaeifard ⁵✉

¹ Associate Professor, Dental Research Center, Dentistry Research Institute, Tehran University of Medical Sciences, Tehran, Iran; Department of Oral Medicine, School of Dentistry, Tehran University of Medical Sciences, Tehran, Iran

² Assistant Professor, Hematology and Oncology and Stem Cell Transplantation Research Center, Tehran University of Medical Sciences, Tehran, Iran

³ Assistant Professor, Laser Research Center of Dentistry, Dentistry Research Institute, Tehran University of Medical Sciences, Tehran, Iran;

Department of Oral Medicine, School of Dentistry, Tehran University of Medical Sciences, Tehran, Iran

⁴ Professor, Drug Design and Development Research Center, Department of Medicinal Chemistry, School of Pharmacy, Tehran University of Medical Sciences, Tehran, Iran

⁵ Postgraduate Student, Department of Oral Medicine, School of Dentistry, Tehran University of Medical Sciences, Tehran, Iran

Abstract

Objectives: Graft-versus-host disease (GVHD) is among the most frequent complications of allogeneic hematopoietic stem cell transplantation (HSCT). GVHD has several clinical manifestations in the oral cavity, including painful desquamative erythema, ulcerative mucosal lesions, and lichenoid lesions. The patients presenting with oral GVHD complain of oral sensitivity, pain, dysgeusia, and xerostomia. The treatment of oral GVHD includes a proper systemic therapy combined with a good oral hygiene and the use of local and topical steroids. Corticosteroids and immunosuppressants are used for the treatment of chronic oral GVHD; however, they are associated with different complications. Evidence shows that curcumin has anti-inflammatory and antioxidative properties. The treatment of lichen planus and oral mucositis with curcumin has been successful. This study aimed to compare the efficacy of topical curcumin in Orabase and triamcinolone in Orabase in the patients affected by oral GVHD.

Materials and Methods: Twenty-six patients presenting with oral GVHD were randomly divided into two groups of 13 using block randomization. The control group used triamcinolone in Orabase, and the case group received curcumin in Orabase.

Results: The two groups were not significantly different in terms of the alleviated severity of the lesions at the end of the treatment ($P=0.052$). The comparison of the pain score via the visual analog scale (VAS) at the onset of the treatment and at days 14 and 28 (completion of the treatment) showed no significant difference between the two groups ($P>0.05$).

Conclusions: Curcumin has comparable efficacy to that of triamcinolone and may be prescribed for the patients presenting with oral GVHD.

Key words: Graft vs Host Disease; Curcumin; Triamcinolone; Orabase

Journal of Dentistry, Tehran University of Medical Sciences, Tehran, Iran (2017; Vol. 14, No. 6)

✉Corresponding author:

S. Babaeifard, Department of Oral Medicine, School of Dentistry, Tehran University of Medical Sciences, Tehran, Iran

shabbabaeifard@yahoo.com

Received: 8 July 2017

Accepted: 12 October 2017

INTRODUCTION

Bone marrow transplantation (BMT) is performed for the treatment of several hematologic conditions and malignancies [1,2]. BMT is performed for the patients who cannot be treated with conventional treatment modalities [1]. Despite the optimal efficacy of BMT for the treatment of some cancers, its complications and side effects are still a matter of debate [3]. Graft-versus-host disease (GVHD) is among

the most common complications of BMT, which can be fatal and has a prevalence rate of 20 to 50% [4]. GVHD is divided into two groups of acute and chronic. Acute GVHD develops three months after the transplantation and mainly involves three organs, namely the skin, gastrointestinal tract, and liver. A maculopapular rash may be seen on the palms of the hands and soles of the feet, which is itchy and/or painful [5]. Acute GVHD may affect any part of the gastrointestinal tract and has

symptoms such as nausea, vomiting, stomach cramps, and diarrhea. Cholestatic jaundice is common in hepatic GVHD, but liver failure is uncommon [5]. The chronic form of GVHD may occur anytime during the first year following the transplantation. In general, the chronic GVHD symptoms do not manifest earlier than 100 days after the transplantation. In the chronic form of GVHD, the oral cavity is among the most commonly involved areas [6].

The overall prevalence rate of GVHD in the patients surviving more than six months after human leukocyte antigen (HLA)-identical BMT is about 30 to 50% [6]. According to the severity of organ involvement, two forms of chronic GVHD may be clinically observed:

1. Limited chronic GVHD: local involvement of the skin or mild liver function impairment.

2. Extensive chronic GVHD: disseminated or local involvement of the skin along with a more severe liver impairment, or involvement of the salivary glands or other organs [7].

In the past years, the incidence of acute GVHD has remained constant, while the incidence of chronic GVHD appears to be increasing [8]. Oral mucosal involvement is seen in over 80% of the patients presenting with GVHD [9]. The oral symptoms of acute GVHD include painful desquamative erythema and ulcerative mucosal lesions, while the oral symptoms of chronic GVHD may include lichenoid, erythematous, and ulcerative lesions. The patients affected by chronic GVHD also suffer from symptoms such as oral sensitivity, pain, dysgeusia, and xerostomia [4,10]. This condition can bear some similarity with autoimmune conditions, such as lupus erythematosus, lichen planus, and Sjogren's syndrome [11].

In 2006, the National Institute of Health (NIH) published a guideline that included parameters for scoring the severity of chronic GVHD (mild, moderate, severe) and the response to treatment in the affected oral areas [12]. Due to the nature of this condition, its treatment includes several therapeutic measures to maximize the therapeutic efficiency. The treatment modalities for oral GVHD include a proper systemic treatment in combination with a good oral hygiene and the use of topical steroids [9,13]. Pharmaceutical

therapy does not prevent the incidence of the chronic GVHD [14]. On the other hand, there is no certain treatment for GVHD, and the efficacy of the treatments seems to be limited [2]. Since 1980, corticosteroids have been used as the first line of treatment for oral GVHD. Moreover, immunosuppressants such as *cyclosporine* are used for the treatment of the chronic oral GVHD [15,16]. The treatment of GVHD may cause complications such as secondary infection, hyperglycemia, hypertension, osteoporosis, renal insufficiency, and hyperlipidemia [17].

Treatment with curcumin has been successful for conditions such as rheumatoid arthritis, postsurgical inflammation, idiopathic orbital inflammation, Alzheimer's disease, multiple myeloma, pancreatic cancer, colon cancer, lichen planus, and mucositis [16-23]. Several studies have demonstrated the anti-inflammatory effects of curcumin [24,25]. It also inhibits apoptosis [26] and has protective effects against organ dysfunction, tissue damage, oxidative stress, and inflammation in response to ischemia. Moreover, it has antioxidant properties, it prevents lipid peroxidation and protects cellular macromolecules such as the DNA. Furthermore, it plays a role in the free oxygen radical scavenging activity [26-29].

To the best of our knowledge, no previous study has assessed the therapeutic efficacy of curcumin in the patients presenting with oral GVHD. Since curcumin has extensive therapeutic, anti-inflammatory, antimicrobial, and antioxidative effects and is nontoxic in its topical form, and by considering the side effects of the medications currently used for the treatment of GVHD [30,31], we aimed to compare the efficacy of topical treatment with curcumin and triamcinolone in the patients affected by oral GVHD.

MATERIALS AND METHODS

This study has been approved by the Ethics Committee of Tehran University of Medical Sciences and is registered at www.irct.ir (IRCT 201508173144N5). All the patients signed informed consent forms prior to participation in the study. Twenty-six patients presenting with oral GVHD and referring to Shariati Hospital of Tehran University of Medical Sciences were evaluated.

Table 1. Demographic characteristics of the patients

Sex	Case				Control			
	Male		Female		Male		Female	
	8		5		7		6	
Type of malignancy	AML	ALL	MM	Hodgkin's lymphoma	AML	ALL	MM	Hodgkin's lymphoma
	9	2	2	0	7	2	3	1
Age (years)	Minimum	Maximum	Mean±SD		Minimum	Maximum	Mean±SD	
	27	49	35.23±7.67		20	58	39.15±12.13	

AML=Acute Myeloid Leukemia, ALL=Acute Lymphoblastic Leukemia, MM=Multiple Myeloma, SD=Standard Deviation

The inclusion criteria consisted of affliction with oral GVHD for a minimum of three months and no use of systemic medications for the treatment of oral lesions in the past three months. The diagnosis of oral GVHD was made and confirmed by an oral medicine specialist and an oncologist.

For the preparation of curcumin in Orabase, 500g of fresh curcumin powder was mixed with 2500ml of 75% ethanol, and the mixture was stored at room temperature overnight. The extract was collected, filtered, and distilled by vacuum distillation to obtain a resin mixture, which was refrigerated. Next, 100g of sodium carboxymethyl cellulose was filtered and added to 900ml of boiling water and was mixed by a magnetic mixer to obtain a stable gel. Afterwards, 10g of the extract was transferred to a 1000-ml beaker glass; 990g of the gel was also added, and the mixture was vigorously stirred for four hours and was transferred to test tubes.

Using block randomization, the patients were divided into two groups of 13. The control group received triamcinolone in Orabase, while the case group used curcumin in Orabase. The clinician was blinded to the group allocation of the patients. The medications were delivered in similar packages and had the same color and form. They were coded using the Microsoft Excel software program. The duration of the study was 28 days [6]. A visual analog scale (VAS) was used to assess the level of the pain severity. The GVHD scoring provided by the NIH was used to assess the severity of the lesions [12].

During the 28-day period, the patients were visited weekly to assess the treatment outcomes. In each session, the changes were determined based on the above-mentioned criteria.

Statistical analysis:

Data were analyzed using SPSS version 22 software program (IBM SPSS Inc., Chicago, IL, USA). $P < 0.05$ was considered statistically significant. The pain scores (according to the VAS) were compared using Mann-U-Whitney test, while the severity of the lesions was analyzed using the covariance test.

RESULTS

Thirteen cases and 13 controls were selected from among the patients presenting to the Hematology and Bone Marrow Transplantation Department of Shariati Hospital during 2015-2016. Table 1 shows the demographic characteristics of the patients. The case and control groups were not significantly different in terms of the malignancy type. All the patients had systemic GVHD and were under treatment with *prednisolone* and *cyclosporine*. The severity of the oral mucosal involvement (mm^2) was compared between the two groups at the baseline and after the treatment. The statistical analysis showed that the mean severity in the case group (curcumin in Orabase) was $9.69 \pm 2.65 \text{mm}^2$ at the baseline and $5.54 \pm 1.61 \text{mm}^2$ after the intervention (Fig. 1).

The mean severity in the control group (triamcinolone

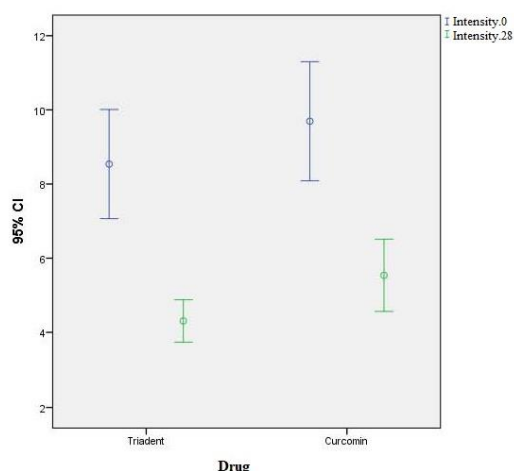


Fig. 1: The error bar of the mean and 95% confidence interval (CI) of the severity of the oral mucosal involvement (mm²) at the baseline and after the treatment in the two groups

in Orabase) was $8.54 \pm 2.43 \text{ mm}^2$ at the baseline and $4.31 \pm 0.94 \text{ mm}^2$ after the intervention (Fig.1).

The comparison of the alleviated severity between the two groups at the end of the treatment showed that the two groups were not significantly different ($P=0.052$).

The comparison of the pain severity by the VAS at the baseline and at days 14 and 28 (completion of the treatment) between the two groups revealed that the mean pain score in the case group was 5.62 ± 1.80 at the baseline, 3.69 ± 1.43 at day 14, and 1.85 ± 1.14 at day 28. The mean pain score in the control group was 6.46 ± 1.89 at the baseline, 4.31 ± 1.75 at day 14, and 2 ± 1.52 at day 28 (Fig. 2).

The severity of the pain at the baseline ($P=0.287$), day 14 ($P=0.362$), and day 28 ($P=0.687$) was not significantly different between the two groups.

DISCUSSION

Allogeneic hematopoietic stem cell transplantation (HSCT) is extensively used for the treatment of hematologic diseases. GVHD is among the most important and most serious complications of HSCT, which is associated with a high morbidity and mortality rate [2]. GVHD involves several organs and compromises the success of HSCT. It also decreases the life expectancy of the patients [14]. In the past couple of years, the prevalence of

acute GVHD has remained constant, affecting 50 to 70% of the patients receiving allogeneic grafts. However, the prevalence of chronic GVHD has increased, as 30 to 50% of the patients who have received allogeneic grafts develop GVHD [8,32]. There is no specific treatment for GVHD, and the efficacy of different treatment modalities is limited. Renal insufficiency, hypertension, hyperglycemia, secondary infection, osteoporosis, and hyperlipidemia are among the complications of GVHD [17]. Half of the patients with chronic GVHD, who have responded well to therapy, show reactivation of GVHD. This reactivation is correlated with the severity of the disease [33].

Systemic treatment is used for severe GVHD, as it involves several organs. The systemic treatment accompanied by local and topical treatments can be used for the patients with oral cavity or skin involvements. Corticosteroids are the medication of choice for the treatment of GVHD and can be used with or without the calcineurin inhibitors [2,4,11,15]. In case of no response to the treatment with corticosteroids and in resistant cases, the second best choice would be extracorporeal *photopheresis* and also *sirolimus*, *everolimus*, *pentostatin*, and *rituximab* [4]. The drugs used for the treatment of GVHD, such as corticosteroids, have several side effects [17]. Some organic compounds including various spices and extracts are used in traditional medicine for wound healing and pain relief. They are rich sources of complex compounds with optimal therapeutic properties and can be effectively used for the treatment of oral GVHD [34,35].

Curcumin is the main active constituent of *turmeric*, derived from the rhizomes (underground stems) of *Curcuma longa* from the family of *Zingiberaceae* [36]. In addition to curcumin (77%), other curcumin-like compounds known as curcuminoids (3%) are also available, including demethoxycurcumin and bisdemethoxycurcumin [37].

However, the pharmaceutical efficacy of *turmeric* powder is due to the presence of 77% curcumin. Curcumin has long been used in Southeast Asia as a spice and also for wound healing and pain and

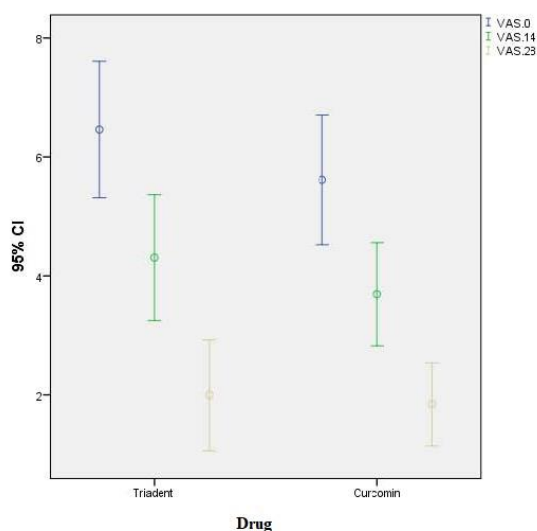


Fig. 2: The error bar of the mean and 95% confidence interval (CI) of the severity of the pain (VAS) in the two groups at different time points

inflammation relief. The efficacy of this compound for the treatment of allergy, dermal wounds, stomachache, jaundice, bloody diarrhea, and chronic diseases such as cancers, neural conditions, cardiovascular conditions, and psychological problems has long been emphasized in traditional medicine. It does not have any significant side effects even at high doses. Such beneficial effects for a material *in vitro* and *in vivo* indicate that it can affect several cellular biochemical pathways [37,38]. Due to these advantages, many studies have focused on curcumin and its pharmaceutical potential. Recent studies have shown that curcumin has several biological properties. It inhibits 5-lipoxygenase (5-LO) and decreases the level of tumor necrosis factor- α (TNF- α), interleukin-1 β (IL-1 β), and interferon- γ (IFN- γ) cytokines and exerts anti-inflammatory [24,25] and antioxidative [39,40] effects. Oxidative stress and TNF- α play a role in the emergence and aggravation of GVHD [41]; this explains the improvement noticed in the curcumin group in our study. Curcumin also has antibacterial, antifungal, antiviral, and disinfecting properties. Evidence shows that secondary infection with *Candida albicans* or alterations in the oral microbial flora can aggravate the oral lesions in GVHD [41]. Thus, due to its antifungal and antibacterial properties,

curcumin may be preferred to the typical steroid therapy for the management of GVHD. Also, curcumin inhibits the transforming growth factor- β (TGF- β) and Caspase-3 and prevents apoptosis [26]. Several studies have shown that curcumin has protective effects against tissue damage, oxidative stress, and inflammation in response to ischemia [26,29].

Cancer is among the long-term complications of oral GVHD [42]. Carcinogenesis is a multistep process, in which different biochemical pathways and the function of many cellular proteins such as transcription factors, cytokines, enzymes, cell-proliferation regulating genes, and apoptosis genes are impaired. Curcumin, with its anticancer properties, affects many pathways and the related proteins [21,29]. In addition, the anticancer property adds to the superiority of curcumin treatment compared to conventional treatments.

Curcumin regulates the pro-angiogenic growth factors such as basic fibroblast growth factor (bFGF) and vascular endothelial growth factor (VEGF), transcription enzymes, angiopoietin-1 and -2, cyclooxygenase-2 (Cox-2), and matrix metalloproteinase-9 (MMP-9) [43-45]. It also has inhibitory effects on bFGF (an angiogenic stimulator). In addition, it down-regulates the expression of the MMP-9 and enzymes required for angiogenesis [44]. In conclusion, curcumin has extensive anti-inflammatory, antimicrobial, and antioxidative properties, is nontoxic when applied topically, and has optimal efficacy for the treatment of rheumatoid arthritis [15], post-surgical inflammation [16], idiopathic orbital inflammation [18], Alzheimer's disease, multiple myeloma [19], pancreatic and colon cancers [21, 22], and oral mucositis, as shown by Mansourian et al [20].

Thus, we compared the efficacy of curcumin and triamcinolone in the patients presenting with oral GVHD [19,20] and showed that the two groups of patients subjected to curcumin in Orabase and triamcinolone in Orabase were not significantly different in terms of the pain (VAS) and severity of the lesions. The anti-inflammatory properties of curcumin, including the inhibitory effect on 5-LO and reducing the level of TNF- α , IL-1 β , and INF- γ [24,25] are probably the reason for the equal efficacy of

triamcinolone (which also has anti-inflammatory effects) and curcumin. Also, by considering the antioxidative properties [39,40] and protective effects against tissue damage and oxidative stress in the treatment of GVHD, curcumin can be used for the patients affected by oral GVHD since it poses fewer complications compared to the currently used drugs.

CONCLUSION

Curcumin in Orabase has comparable efficacy to that of triamcinolone in Orabase and may be beneficial for the treatment of the patients presenting with oral GVHD.

REFERENCES

- 1- Ferrara JL, Deeg HJ. Graft-versus-host disease. *N Engl J Med*. 1991 Mar;324(10):667-74.
- 2- Jaglowski SM, Devine SM. Graft-versus-host disease: why have we not made more progress? *Curr Opin Hematol*. 2014;21(2):141-7.
- 3- Kuten-Shorrer M, Woo SB, Treister NS. Oral graft-versus-host disease. *Dent Clin North Am*. 2014 Mar;58(2):351-68.
- 4- Dignan FL, Amrolia P, Clark A, Cornish J, Jackson G, Mahendra P, et al. Diagnosis and management of chronic graft-versus-host disease. *Br J Haematol*. 2012 Jul;158(1):46-61.
- 5- Demarosi F, Lodi G, Carrassi A, Soligo D, Sardella A. Oral malignancies following HSCT: graft versus host disease and other risk factors. *Oral Oncol*. 2005 Oct;41(9):865-77.
- 6- Treister NS, Cook EF Jr., Antin J, Lee SJ, Soiffer R, Woo SB. Clinical evaluation of oral chronic graft-versus-host disease. *Biol Blood Marrow Transplant*. 2008 Jan;14(1):110-5.
- 7- Kurosawa S, Oshima K, Yamaguchi T, Yanagisawa A, Fukuda T, Kanamori H, et al. Quality of Life after Allogeneic Hematopoietic Cell Transplantation According to Affected Organ and Severity of Chronic Graft-versus-Host Disease. *Biol Blood Marrow Transplant*. 2017 Oct;23(10):1749-1758.
- 8- Travnik R, Beckers M, Wolff D, Holler E, Landthaler M, Karrer S. Graft-versus-Host Disease (GvHD)-an update: Part 1: Pathophysiology, clinical features and classification of GvHD. *Hautarzt*. 2011 Feb;62(2):139-54.
- 9- Brown RS, Edwards D, Walsh-Chocolaad T, Childs RW. Topical tacrolimus with custom trays in the treatment of severe oral chronic graft-versus-host disease refractory to a potent topical steroid therapy: a case report. *Oral Surg Oral Med Oral Pathol Oral Radiol*. 2013 Apr;115(4):e26-30.
- 10- Noce CW, Gomes A, Shcaira V, Correa ME, Moreira MC, Silva Junior A, et al. Randomized double-blind clinical trial comparing clobetasol and dexamethasone for the topical treatment of symptomatic oral chronic graft-versus-host disease. *Biol Blood Marrow Transplant*. 2014 Aug;20(8):1163-8.
- 11- Imanguli MM, Atkinson JC, Mitchell SA, Avila DN, Bishop RJ, Cowen EW, et al. Salivary gland involvement in chronic graft-versus-host disease: prevalence, clinical significance, and recommendations for evaluation. *Biol Blood Marrow Transplant*. 2010 Oct;16(10):1362-9.
- 12- Pavletic SZ, Martin P, Lee SJ, Mitchell S, Jacobsohn D, Cowen EW, et al. Measuring therapeutic response in chronic graft-versus-host disease: National Institutes of Health Consensus Development Project on Criteria for Clinical Trials in Chronic Graft-versus-Host Disease: IV. Response Criteria Working Group Report. *Biol Blood Marrow Transplant*. 2006 Mar;12(3):252-66.
- 13- Pereira CM, de Almeida OP, Correa ME, Souza CA, Barjas-Castro ML. Oral involvement in chronic graft versus host disease: a prospective study of 19 Brazilian patients. *Gen Dent*. 2007 Jan-Feb;55(1):48-51.
- 14- Linhares YP, Pavletic S, Gale RP. Chronic GVHD: Where are we? Where do we want to be? Will immunomodulatory drugs help? *Bone Marrow Transplant*. 2013 Feb;48(2):203-9.
- 15- Salmasian H, Rohanizadegan M, Banihosseini S, Rahimi Darabad R, Rabbani-Anari M, Shakiba A, et al. Corticosteroid regimens for treatment of acute and chronic graft versus host disease (GvHD) after allogeneic stem cell transplantation. *Cochrane Database Syst Rev*. 2010 Jan;20;(1):CD005565.
- 16- Imanguli MM, Pavletic SZ, Guadagnini JP, Brahim JS, Atkinson JC. Chronic graft versus host disease of oral mucosa: review of available therapies.

- Oral Surg Oral Med Oral Pathol Oral Radiol Endod. 2006 Feb;101(2):175-83.
- 17- Arora M. Therapy of chronic graft-versus-host disease. *Best Pract Res Clin Haematol*. 2008 Jun;21(2):271-9.
- 18- Deodhar SD, Sethi R, Srimal RC. Preliminary study on antirheumatic activity of curcumin (diferuloyl methane). *Indian J Med Res*. 1980 Apr;71:632-4.
- 19- Satoskar RR, Shah SJ, Shenoy SG. Evaluation of anti-inflammatory property of curcumin (diferuloyl methane) in patients with postoperative inflammation. *Int J Clin Pharmacol Ther Toxicol*. 1986 Dec;24(12):651-4.
- 20- Mansourian A, Amanlou M, Shirazian S, Jahromi ZM, Amirian A. The effect of "Curcuma Longa" topical gel on radiation-induced oral mucositis in patients with head and neck cancer. *Iran J Radiat Res*. 2015 Jul;13(3):269-74.
- 21- Hatcher H, Planalp R, Cho J, Torti FM, Torti SV. Curcumin: from ancient medicine to current clinical trials. *Cell Mol Life Sci*. 2008 Jun;65(11):1631-52.
- 22- Lao CD, Ruffin MT 4th, Normolle D, Heath DD, Murray SI, Bailey JM, et al. Dose escalation of a curcuminoid formulation. *BMC Complement Altern Med*. 2006 Mar 17;6:10.
- 23- Clarkson MR, Friedewald JJ, Eustace JA, Rabb H. Acute Kidney Injury, in: Brenner B, (editor), Brenner & Rector's: The Kidney. Philadelphia: Saunders Elsevier, 2007:943-87.
- 24- Srimal RC, Dhawan BN. Pharmacology of diferuloyl methane (curcumin), a non-steroidal anti-inflammatory agent. *J Pharm Pharmacol*. 1973 Jun;25(6):447-52.
- 25- Kuhad A, Pikhwal S, Sharma S, Tirkey N, Chopra K. Effect of curcumin on inflammation and oxidative stress in cisplatin-induced experimental nephrotoxicity. *J Agric Food Chem*. 2007 Dec;55(25):10150-5.
- 26- Awad AS, El-Sharif AA. Curcumin immune-mediated and anti-apoptotic mechanisms protect against renal ischemia/reperfusion and distant organ induced injuries. *Int Immunopharmacol*. 2011 Aug;11(8):992-6.
- 27- Shoskes DA. Effect of bioflavonoids quercetin and curcumin on ischemic renal injury: a new class of renoprotective agents. *Transplantation*. 1998 Jul;66(2):147-52.
- 28- Bayrak O, Uz E, Bayrak R, Turgut F, Atmaca AF, Sahin S, et al. Curcumin protects against ischemia/reperfusion injury in rat kidneys. *World J Urol*. 2008 Jun;26(3):285-91.
- 29- Sefidan AM, Mohajeri D. Preventive effects of turmeric (*Curcuma longa* Linn) on renal ischemia-reperfusion injury in rats. *Adv Biores*. 2013 Dec;4(4):40-6.
- 30- Ruby AJ, Kuttan G, Babu KD, Rajasekharan KN, Kuttan R. Anti-tumour and antioxidant activity of natural curcuminoids. *Cancer Lett*. 1995 Jul;94(1):79-83.
- 31- Ramsewak RS, DeWitt DL, Nair MG. Cytotoxicity, antioxidant and anti-inflammatory activities of curcumins I-III from *Curcuma longa*. *Phytomedicine*. 2000 Jul;7(4):303-8.
- 32- Elad S, Zeevi I, Or R, Resnick IB, Dray L, Shapira MY. Validation of the National Institutes of Health (NIH) scale for oral chronic graft-versus-host disease (cGVHD). *Biol Blood Marrow Transplant*. 2010 Jan;16(1):62-9.
- 33- Perez-Simon JA, Encinas C, Silva F, Arcos MJ, Diez-Campelo M, Sanchez-Guijo FM, et al. Prognostic factors of chronic graft-versus-host disease following allogeneic peripheral blood stem cell transplantation: the national institutes health scale plus the type of onset can predict survival rates and the duration of immunosuppressive therapy. *Biol Blood Marrow Transplant*. 2008 Oct;14(10):1163-71.
- 34- Cassileth BR, Deng G. Complementary and alternative therapies for cancer. *Oncologist*. 2004 Feb;9(1):80-9.
- 35- Singh S. From exotic spice to modern drug? *Cell*. 2007 Sep;130(5):765-8.
- 36- Ammon HP, Wahl MA. Pharmacology of *Curcuma longa*. *Planta Med*. 1991 Feb;57(1):1-7.
- 37- Shishodia S, Chaturvedi MM, Aggarwal BB. Role of curcumin in cancer therapy. *Curr Probl Cancer*. 2007 Jul-Aug;31(4):243-305.
- 38- Aggarwal BB, Sung B. Pharmacological basis for the role of curcumin in chronic diseases: an age-old spice with modern targets. *Trends Pharmacol Sci*. 2009 Feb;30(2):85-94.
- 39- Masuda T, Hidaka K, Shinohara A, Maekawa T, Takeda Y, Yamaguchi H. Chemical studies on antioxidant mechanism of curcuminoid: analysis of radical reaction products from curcumin. *J Agric*

- Food Chem. 1999 Jan;47(1):71-7.
- 40-Tirkey N, Kaur G, Vij G, Chopra K. Curcumin, a diferuloylmethane, attenuates cyclosporine-induced renal dysfunction and oxidative stress in rat kidneys. *BMC Pharmacol.* 2005 Oct 15;5:15.
- 41- Lin MT, Storer B, Martin PJ, Tseng LH, Gooley T, Chen PJ, et al. Relation of an interleukin-10 promoter polymorphism to graft-versus-host disease and survival after hematopoietic-cell transplantation. *N Engl J Med.* 2003 Dec 4;349(23):2201-10.
- 42- Elsaadany BA, Ahmed EM, Aghbary SMH. Efficacy and Safety of Topical Corticosteroids for Management of Oral Chronic Graft versus Host Disease. *Int J Dent.* 2017;2017:1908768.
- 43- Gururaj AE, Belakavadi M, Venkatesh DA, Marme D, Salimath BP. Molecular mechanisms of anti-angiogenic effect of curcumin. *Biochem Biophys Res Commun.* 2002 Oct;297(4):934-42.
- 44- Mohan R, Sivak J, Ashton P, Russo LA, Pham BQ, Kasahara N, et al. Curcuminoids inhibit the angiogenic response stimulated by fibroblast growth factor-2, including expression of matrix metalloproteinase gelatinase B. *J Biol Chem.* 2000 Apr;275(14):10405-12.
- 45- Yoysungnoen P, Wirachwong P, Bhattarakosol P, Niimi H, Patumraj S. Effects of curcumin on tumor angiogenesis and biomarkers, COX-2 and VEGF, in hepatocellular carcinoma cell-implanted nude mice. *Clin Hemorheol Microcirc.* 2006 Jan;34(1-2):109-15.